

The Axillary Arch: Anatomy and Suggested Clinical Manifestations

A. Russell Smith, Jr, PT, EdD, OCS, FAAOMPT¹
John P. Cummings, PT, PhD²

The purpose of this commentary is to describe bilateral anomalous bands of the latissimus dorsi muscle observed in an 81-year-old male embalmed cadaver, and to discuss the possible clinical implications of this anomaly. The musculotendinous bands tautened and compressed the underlying axillary vessels, and the musculocutaneous, median, and ulnar nerves during passive abduction/external rotation of the shoulder. Similar variations found in the latissimus dorsi muscles in this commentary have been reported in the anatomical and surgical literature. These reports include descriptions of the anomalous bands of the latissimus dorsi attaching to the coracoid process, pectoralis major muscle, and fascia of the coracobrachialis muscle. The potential presence of an axillary arch presents several clinical considerations for the physical therapist. The existence of an axillary arch should be considered in patients with signs and symptoms consistent with upper extremity neurovascular compromise similar to thoracic outlet syndrome. Including this variant in the differential diagnostic process may assist physical therapists in the management of patients with signs and symptoms consistent with thoracic outlet syndrome. *J Orthop Sports Phys Ther* 2006;36(6):425-429. doi:10.2519/jospt.2006.2120

Key Words: axilla, brachial plexus, latissimus dorsi, thoracic outlet

During routine dissection of an 81-year-old male embalmed cadaver in a gross anatomy course for physical therapy students, bilateral anomalous bands of the latissimus dorsi, consistent with the axillary arch of Langer, were observed. The caudal and cranial attachments were identified, and the length and width of the muscular bands were measured. The dissected axillary arches were digitally photographed with the shoulder abducted and externally rotated (Figures 1, 2, and 3). The Anatomical Board of Florida granted permission for use of the cadaver for this study.

OBSERVATIONS

Symmetrical, musculotendinous slips or bands were observed arising from the superiomedial aspect of the latissimus dorsi muscle at the level of the third rib. This anatomical variation was present bilaterally. The musculotendinous bands attached to the investing fascia on the anterior surface of the coracobrachialis muscle, immediately distal to the proximal myotendinous junction. The bands were symmetrical, measuring 8.0 cm in length (6.0-cm muscle belly with a 2.0-cm tendon) and 0.5 cm in breadth. No separate innervation was noted in either muscle with a typical innervation of the latissimus by the thoracodorsal nerve.¹⁹

The musculotendinous bands tautened and compressed the underlying structures during passive abduction/external rotation of the shoulder. The structures passing deep to the musculotendinous band included the axillary vessels and the musculocutaneous, median, and ulnar nerves (Figures 1, 2, and 3).

LITERATURE REVIEW

Similar variations found in the latissimus dorsi muscles in this commentary have been reported in the anatomical^{1,2,4,9} and surgical literature.^{3,6,13,14,15} These reports include descriptions of the anomalous bands of the latissimus dorsi attaching to the coracoid process,⁹ pectoralis major muscle,^{3,14,15} and fascia of the coracobrachialis muscle.^{1,6,9}

Merida-Velasco et al⁹ reported axillary arches in 3 of 32 dissected cadavers, bilateral in 1 case and unilateral in 2 cases. These authors also noted that 2 variations of the axillary arch had been reported by Testut in 1884 (a complete form extending from the latissimus dorsi to the insertion of the pectoralis major and an incomplete form extending from the latissimus dorsi to either the axillary fascia, biceps brachii muscle, coracobrachialis muscle, pectoralis minor muscle, or to the coracoid process). Merida-Velasco et al⁹ reported that the cadaver with the bilateral anomaly presented with the complete form, measuring

¹ Associate Professor, Physical Therapy Program, University of North Florida, Jacksonville, FL.

² Associate Professor, Physical Therapy Program, University of North Florida, Jacksonville, FL.

The Anatomical Board of Florida granted permission for use of the cadaver in this study.

Address correspondence to A. Russell Smith, Jr, Department of Athletic Training and Physical Therapy, University of North Florida, 4567 St Johns Bluff Road South, Jacksonville, FL 32224. E-mail: arsmith@unf.edu

9.0 × 0.6 cm on one side and 4.0 × 1.0 cm on the other side. Both arches were innervated by the thoracodorsal nerve and crossed the axillary neurovascular bundle anteriorly. The third and fourth anomalies described by Merida-Velasco et al⁹ were of the incomplete form and measured 7.0 × 0.6 cm and 12.5 × 1.5 cm. The third anomaly, also innervated by the thoracodorsal nerve, crossed anterior to the axillary neurovascular bundle and attached to the coracobrachialis muscle. The fourth anomalous axillary arch, innervated by the medial pectoral nerve, passed posterior to the axillary neurovascular bundle and attached to the coracoid process. The radial nerve was located posterior to the anomalous band.

Merida-Velasco et al⁹ hypothesized that the first 3 variations could cause compression of the neurovascular structures passing deep to the anomalous bands of the latissimus dorsi muscle. The authors also stated that the anatomical variations observed in their dissections could contribute to hyperabduction syndrome, which is typically considered to be related to compression by the pectoralis minor and/or clavipectoral fascia. Furthermore, the authors suggested that compression of the radial nerve might have occurred in the fourth case where

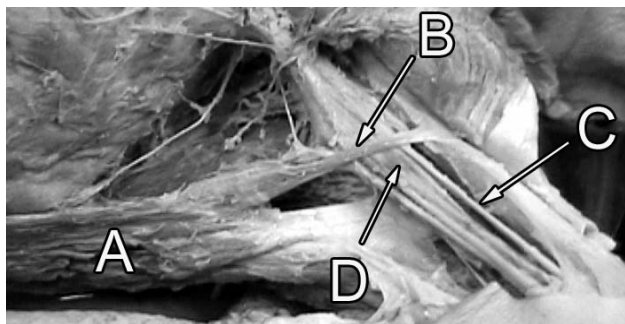


FIGURE 1. Anterior view of left shoulder. (A) latissimus dorsi, (B) axillary arch, (C) musculocutaneous nerve, (D) axillary vessels.

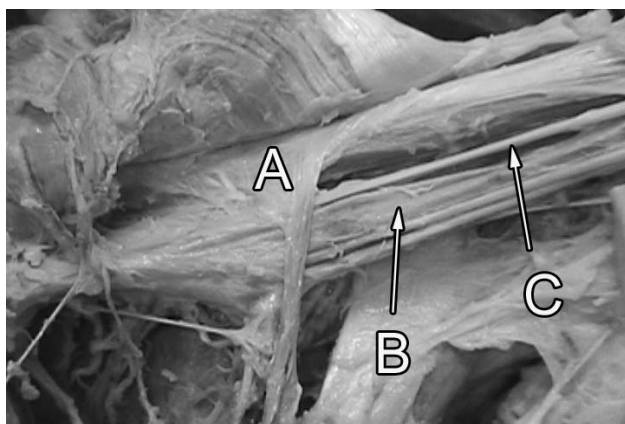


FIGURE 2. Anterior view of left shoulder. (A) aponeurotic attachment of the axillary arch into the fascia of the coracobrachialis, (B) axillary vessels, (C) musculocutaneous nerve.




FIGURE 3. Anterior view of right shoulder. (A) axillary arch, (B) coracobrachialis muscle, (C) median nerve, (D) ulnar nerve.

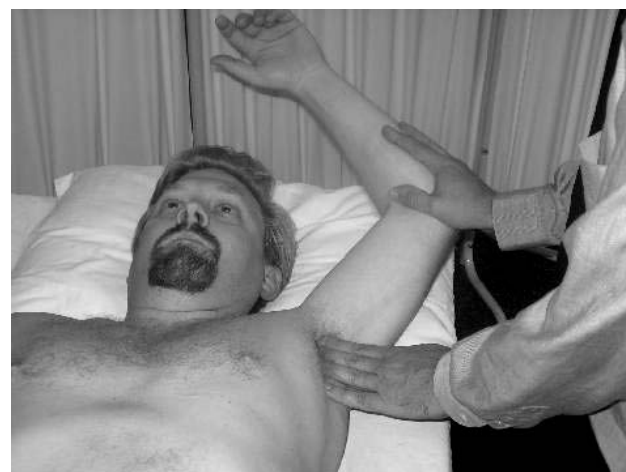

FIGURE 4. Assessment for axillary arch.

the radial nerve was located posterior to the muscular axillary arch. Merida-Velasco et al⁹ added that clinicians should examine for the presence of an axillary arch in patients with signs and symptoms of cervico-axillary compression.

Similar to our findings, Kalaycioglu et al⁶ also observed an anomalous band of the right latissimus dorsi in a cadaver arising from the base of the axillary fossa, crossing anterior to the median and ulnar nerves and the brachial vessels, and inserting into the fascia of the coracobrachialis muscle. The band of muscle described by Kalaycioglu et al⁶ was innervated by the thoracodorsal nerve, and measured 4.3 cm in length and 0.4 cm in width. They stated that such an anomalous fasciculus of the latissimus dorsi muscle was reported in the literature to have an incidence rate ranging from 2% to 8%. The anomalous band of muscle was positioned in such a manner as to possibly compress the underlying structures (median and ulnar nerves, and brachial artery and vein) when the arm is extended, abducted, and externally rotated. They added that compression of the median and ulnar nerves and the brachial vessels

could lead to circulatory deficiency, chronic pain, and paresthesias in the arm, forearm, and hand.

Yuskel et al²⁰ also reported an axillary arch arising from the upper margin of the latissimus dorsi. However, instead of inserting into the fascia of the coracobrachialis muscle fibers, the arch intermingled with the fibers of the pectoralis major. The anomalous band was innervated by the thoracodorsal nerve.

The bilateral axillary arches described in the current commentary are consistent with the type described by Bergman,¹ Kalaycioglu et al,⁶ and Merida-Velasco et al,⁹ with a distal attachment to the coracobrachialis fascia. The bilateral musculotendinous bands of the latissimus dorsi muscle we observed measured 8.0 cm in length and 0.5 cm in breadth, consistent in size with previously reported axillary arches reported as measuring 7.0 to 10.0 cm in length and 0.5 to 1.5 cm in breadth. Consistent with the cases reported by Kalaycioglu et al,⁶ the median nerve, ulnar nerve, and axillary vessels passed posterior to the arch. The position of each arch in this study may exert pressure on the underlying neurovascular structures during abduction and external rotation of the shoulder.

CLINICAL IMPLICATIONS

This anomaly has heretofore not been presented in the physical therapy literature and, based on the authors' experiences, has not been appreciated as a possible cause of thoracic outlet syndrome in physical therapy clinics. Including this variant in the differential diagnostic process may assist physical therapists in the management of patients with signs and symptoms consistent with thoracic outlet syndrome. Several reports in the surgical literature describe the presence of axillary arches.^{3,14,15,16} The presence of an axillary arch has been demonstrated to possibly be symptomatic¹³ or asymptomatic.³

Sachatello¹³ reported the case of a 15-year-old girl with signs and symptoms later related to the presence of an axillary arch identified during surgical exploration. The patient gave a 6-week history of intermittent blue discoloration and swelling of the right arm and hand. The patient's symptoms began while participating in gymnastics. The symptoms increased when hanging from the rings. Physical examination demonstrated edema and blue discoloration of the right hand. Severe venous engorgement and cyanosis of the right hand was produced with supine position with the right hand placed on the back of the head. The engorgement and cyanosis would subside totally following placing the right hand on the chest. Fullness of the right axilla was noted with a loss of the normal concavity. Sachatello¹³ reported that the axillary mass was more visible than palpable. Surgical exploration of the right axilla revealed a taut, 1.0-cm-wide axillary arch extending from the upper latissimus dorsi to the humeral insertion of the pectoralis

major. The arch was observed to become taut with shoulder extension and elevation, with concomitant compression of the axillary neurovascular bundle. Surgical excision of the anomalous musculofibrous band relieved the patient's signs and symptoms with no recurrence during a 4-year follow-up.

Daniels and Rovere³ reported finding an axillary arch in a 49-year-old female during routine axillary surgical dissection. Initially, a muscular band was considered to be the latissimus dorsi muscle, but further dissection revealed an axillary arch from the lateral edge of the latissimus dorsi muscle extending across the anterior aspect of the axillary neurovascular bundle to attach to the insertion of the pectoralis major. The patient was questioned following the surgical dissection and reported no previous upper limb neurovascular signs or symptoms. Daniels and Rovere³ hypothesized the possibility of several clinical implications of the presence of an axillary arch, including axillary venous thrombosis and upper limb lymphedema.

Serpel and Baum¹⁵ described finding an axillary arch in a 60-year-old woman undergoing a simple mastectomy. During the surgical procedure, the authors documented the presence of an axillary arch, measuring 7.0 × 1.0 cm. The anomaly arose from the anterior margin of the latissimus dorsi in the middle of the posterior axillary fold and tapered into a tendon with attachment to the pectoralis major tendon. The authors added they had encountered 4 similar cases out of approximately 2000 surgical cases for an incidence rate of 0.25%.

Serpel and Baum¹⁵ also suggested that the presence of an axillary arch might contribute to axillary vein compression with subsequent upper extremity lymphedema. The authors recommended surgical removal of the axillary arch if found during axillary surgery. The clinical presentation proposed by Serpel and Baum¹⁵ includes visible axillary fullness with loss of the normal axillary concavity, and the presence of a palpable axillary mass with the shoulder in abduction that is absent when the arm returns to the side. Additional possible clinical manifestations of the axillary arch include infraclavicular median nerve entrapment, venous engorgement, and edema consistent with hyperabduction syndrome.^{5,7,9,13,16}

Saitta and Baum¹⁴ presented a case report of a 10-year-old boy with an asymptomatic right axillary mass. Physical examination revealed a loss of the axillary concavity with a palpable right axillary mass with the abduction of the arm to 90°. The mass appeared to disappear when the arm was returned to the patient's side. Surgical exploration of the right axilla revealed an 8-cm anomalous band from the latissimus dorsi to the pectoralis major humeral attachment, anterior to the neurovascular structures. Surgical resection was performed with no residual disability.

In another report in the surgical literature, Kutiyawala et al⁷ documented the anatomy of the axilla in 100 patients undergoing surgical intervention for invasive primary breast cancer. In 6 patients anomalies consistent with an axillary arch were observed. Two of these patients had muscular bands attaching the latissimus dorsi to the coracoid process and the remaining 4 patients had muscular bands attaching the latissimus dorsi to the pectoralis major muscle, all crossing anterior to the axillary vessels and nerves.

DISCUSSION

Thoracic outlet syndrome, a term first coined by Peet¹¹ in 1956, has classically referred to various disorders compromising the neurovascular structures passing through the thoracic outlet.^{11,12,17,18} Three anatomical regions frequently proposed to be the major sites of compromise of the neurovascular structures are the interscalene triangle, costoclavicular space, and subcoracoid triangle.⁸ Compromise has been related to anatomical variation of the scalene muscles,^{8,12} cervical ribs,^{8,11,12} osteophytes,¹² and altered posture.^{17,18} One anatomical variation reported in the anatomical and surgical literature, but not discussed in the physical therapy literature, as a possible cause of thoracic outlet syndrome is a variation of the latissimus dorsi termed the “axillary arch.”^{1,3,4,7,9} Musculotendinous slips or bands of the latissimus dorsi have been reported to insert into various structures including the coracoid process,^{1,4,7,9} pectoralis major tendon,^{1,2,3,7,9,15} pectoralis minor muscle,¹⁰ and coracobrachialis fascia.^{1,4,9} These variations have been collectively referred to as the “axillary arch” or “Langer’s axillary arch.” The incidence of an axillary arch in the general population has been reported as ranging from 2%⁶ to 7%.^{1,7,9} Although the axillary arch has been implicated clinically as a potential cause of neurovascular compression of the axillary neurovascular bundle, particularly axillary vein obstruction with resultant swelling, discoloration, and lymphedema,^{5,13,16} there are no reports of the anomaly causing neurological compression in the literature. One possible reason for the lack of such a report is that clinicians are not aware of the presence of the anomaly.

Based on our findings and a thorough review of the literature, the potential presence of an axillary arch presents several clinical considerations for the physical therapist. The existence of an axillary arch should be considered in patients with signs and symptoms consistent with upper extremity neurovascular compromise similar to thoracic outlet syndrome. Visible and palpable structural changes, including a fullness of the axilla with loss of the normal concavity, particularly with increased axillary prominence during combined shoulder elevation and external rotation, may indicate the presence of an

axillary arch. Resisted shoulder adduction and internal rotation, particularly in an abducted position, may be expected to reproduce upper extremity signs or symptoms and increase the prominence of the arch. We further propose that reproduction of symptoms may also occur with the application of pressure over the neurovascular bundle near the distal attachment of the axillary arch with the shoulder fully flexed and externally rotated, consistent with a Tinel test. Figure 4 illustrates a proposed clinical test to assess the possible presence and contribution of an axillary arch in patients with thoracic outlet syndrome. Similar to the hyperabduction test, the patient’s shoulder is positioned in full elevation with external rotation. The axilla is palpated, assessing for fullness with particular attention to the lateral border of the latissimus. Isometric resisted internal rotation and extension action is then performed with continued palpation of the axilla. Patient signs and symptoms are monitored throughout the sequencing.

CONCLUSION

Bilateral anomalous bands of the latissimus dorsi muscle were found in an 81-year-old male cadaver. The bands passed anterior to the axillary neurovascular bundle and blended distally with the fascia of the coracobrachialis. The anomaly reported in this paper is consistent with the axillary arch or “Arch of Langer” described in the anatomical and surgical literature. Given our findings, we suggest that clinicians consider the possibility of the presence of an axillary arch in clients demonstrating involvement of the components of the axillary neurovascular bundle. Future publications should include case reports of patients with the presence of an axillary arch, with discussion of the role of the arch relative to signs and symptoms consistent with thoracic outlet syndrome.

REFERENCES

1. Bergman RA, Thompson SA, Afifi AK. *Catalog of Human Variation*. Baltimore, MD: Urban & Schwarzenberg; 1984.
2. Bonastre V, Rodriguez-Niedenfuhr M, Choi D, Sanudo JR. Coexistence of a pectoralis quartus muscle and an unusual axillary arch: case report and review. *Clin Anat*. 2002;15:366-370.
3. Daniels IR, della Rovere GQ. The axillary arch of Langer—the most common muscular variation in the axilla. *Breast Cancer Res Treat*. 2000;59:77-80.
4. Dharap A. An unusually medial axillary arch muscle. *J Anat*. 1994;184(Pt 3):639-641.
5. Hughes JH, Patel AR. Swelling of the arm following radical mastectomy. *Br J Surg*. 1966;53:4-14.

6. Kalaycioglu A, Gumusalan Y, Ozan H. Anomalous insertional slip of latissimus dorsi muscle: arcus axillaris. *Surg Radiol Anat.* 1998;20:73-75.
7. Kutiyanawala MA, Stotter A, Windle R. Anatomical variants during axillary dissection. *Br J Surg.* 1998;85:393-394.
8. Mackinnon SE, Novak CB. Thoracic outlet syndrome. *Curr Probl Surg.* 2002;39:1070-1145.
9. Merida-Velasco JR, Rodriguez Vazquez JF, Merida Velasco JA, Sobrado Perez J, Jimenez Collado J. Axillary arch: potential cause of neurovascular compression syndrome. *Clin Anat.* 2003;16:514-519.
10. Miyauchi R. A very rare variation of the latissimus dorsi muscle--a case with accessory insertion of the latissimus dorsi muscle into the first rib and into the pectoralis minor muscle. *Okajimas Folia Anat Jpn.* 1982;58:521-534.
11. Peet RM, Henriksen JD, Anderson TP, Martin GM. Thoracic-outlet syndrome: evaluation of a therapeutic exercise program. *Mayo Clin Proc.* 1956;31:281-287.
12. Roos DB, Owens JC. Thoracic outlet syndrome. *Arch Surg.* 1966;93:71-74.
13. Sachatello CR. The axillopectoral muscle (Langer's axillary arch): a cause of axillary vein obstruction. *Surgery.* 1977;81:610-612.
14. Saitta GF, Baum V. Langer's axillary arch. An unusual cause of axillary mass. *JAMA.* 1962;180:690.
15. Serpell JW, Baum M. Significance of 'Langer's axillary arch' in axillary dissection. *Aust N Z J Surg.* 1991;61:310-312.
16. Tilney ML, Griffiths HJ, Edwards EA. Natural history of major venous thrombosis of the upper extremity. *Arch Surg.* 1970;101:792-796.
17. Urschel HC, Jr., Razzuk MA. Neurovascular compression in the thoracic outlet: changing management over 50 years. *Ann Surg.* 1998;228:609-617.
18. Walsh MT. Therapist management of thoracic outlet syndrome. *J Hand Ther.* 1994;7:131-144.
19. Warwick R, Williams P. *Gray's Anatomy.* 38th ed. Philadelphia, PA: W.B. Saunders; 1993.
20. Yuksel M, Yuksel E, Surucu S. An axillary arch. *Clin Anat.* 1996;9:252-254.